



vInnovate Technologies



Presents

vAldeMedical

Generative AI in Healthcare

AI-powered insights for better decisions





vInnovate Technologies



Our Technology Partners



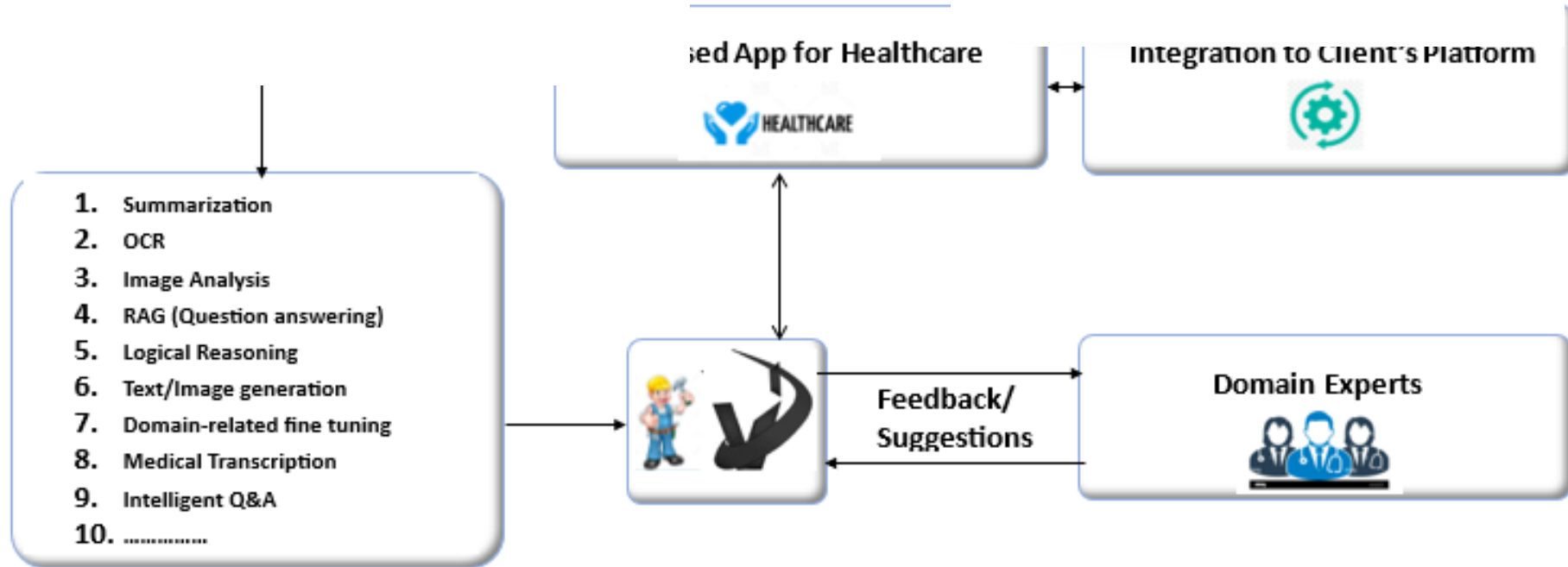
Microsoft Azure



The Power of Generative AI by Google and OpenAI

The Power They Bring to Our Products





vInnovate Technologies

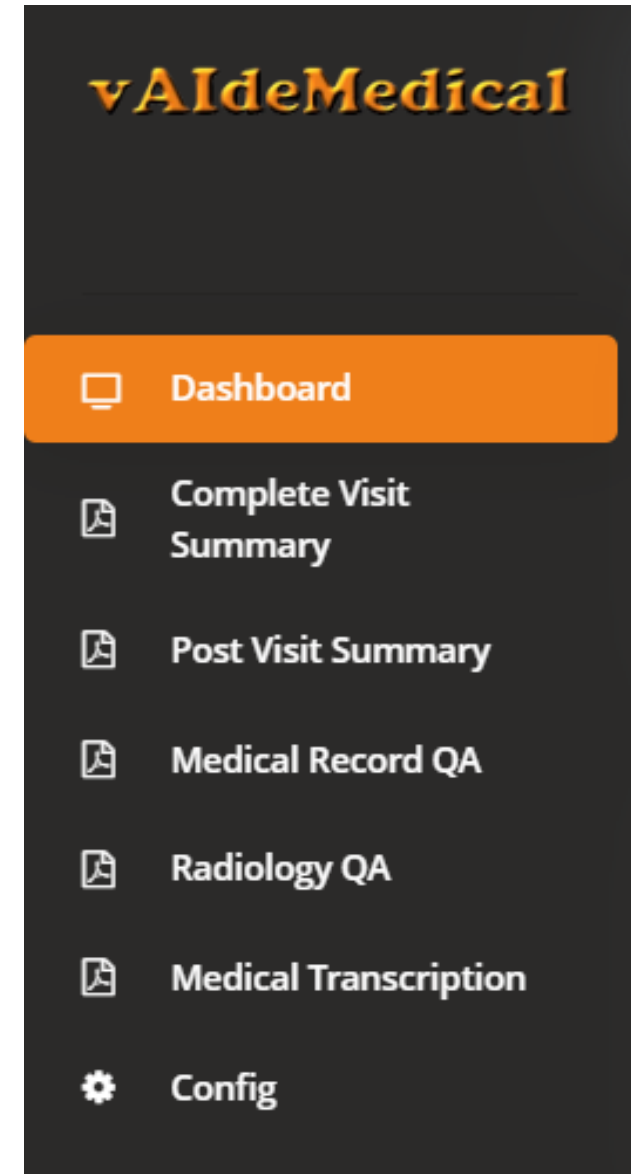
Healthcare:



vAIdMedical

A Functional Overview

A Suite of functions to access the power of Generative AI to extract data from documents, scans, speech records, etc. Then to analyze, summarize, clarify and answer questions about the data to support medical diagnosis and treatment.





All Types of Data Sources

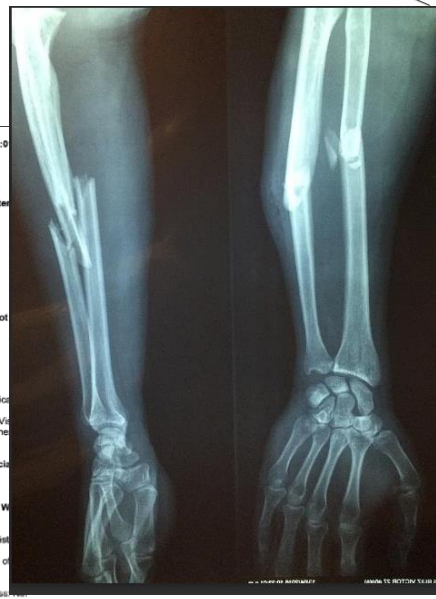Reports, Prescriptions, Charts, Scans, Handwritten Notes, Voice Recordings, Foreign Languages (including Arabic and other scripts) ...

Handwritten prescription form:

Name: *Aswanda Cognia*
 Address: *West Kumbho, Makati City*
 Age: *29* Sex: *M* Date: *12-03-20*
Cap # 21
 Rx (4 mins)
Amoxicillin
 Sig: *1 cap*

Medical report snippet:

Date: 08/03/2020 Time In: 3:10 PM Time Out: 4:00
 Patient Name: *Brandon Cielinski* Social Security: *XXX-XX-4701*
 Home Phone: *210-525-7807*
 Employer: *ABC Home & Commercial Services - San Antonio* Industrial Director: *Brandy Hall*
 Primary Contact: *Isabel Fierro* Treating Doctor: *Danielle Coulter*
 Phone: *512-437-4500 ext 1465* Claim Number:
 Services Requested
 Date of Initial Visit: *08/03/2020*
 Date of Injury: *07/29/2020*
 Last Worked: *08/01/2020*
 Description of Injury:
 Patient states that he over extended his right arm while pulling himself into tight spot and pain in his right shoulder.
 Previous Treatment/Emergency room visit for THIS INJURY
 None
 Subjective Complaints (what patient states):
 Patient states that pain on right shoulder that has not improved with over the counter medicine.
 Shoulder: Patient presents to the clinic for a. Right shoulder complaint.
 RIGHT: Decreased range of motion abduction and flexion. Patient reports a pain level of (Numbness and tingling is reported for the upper extremities); No. Upper extremity weakness reported. No. Bruising is reported. No.
 Reviewed Family Medical History, Past Medical History, Review of Systems, and Social form and/or the patient.
 Exam/Results:
 Physical: Blood pressure 110 / 86. Pulse 72. Respiratory rate 16. Height (inches) 74. Weight 177. BSA (m²): 2.26. Age 34.
 General: Alert and oriented to time, place, and person: Yes. Affect normal. Gait normal. Deep tendon reflexes: No. Well developed: Yes. Well nourished: Yes.
 Head and Neck: Range of motion normal. Normo-cephalic and non-traumatic: Yes. Exam of thyroid normal.
 Neuro: Cranial nerves II-XII are intact: Yes. Normal rhomboids: Yes.
 Ear, Nose, Throat: Mucosal erythema noted: No. Lymphadenopathy: No. Sinus tenderness: No.
 Heart: Regular rate and rhythm without murmur: Yes.
 Extremities: Extremities edema or varicosities: No.
 Lungs: Clear to auscultation bilaterally: Yes. Use of accessory muscle: No.
 ABD: Benign: Yes. Pulsatile masses: No. Evidence of hernia: No.
 Shoulder:
 RIGHT: Inspection no obvious deformity. Tenderness anterior lateral. Range of motion 80 degrees abduction, 140 degrees flexion. Normal external rotation. Normal internal rotation. Normal extension. Muscle testing weak SITS muscles. Impingement is positive: Yes. Positive surcus sign: No. Deep tendon reflexes are normal: Yes. Dislocation: No.
 X-rays:



Handwritten notes:

Shri Shri Krupa
 Reg No: 0015
 Patient Name: BI
 BP 190
 Pulse 56.00
 34.00
 34.00
 120.00
 120.00
 80.00
 80.00

Bharat Enterprises		INVOICE		Phone: 9420290023
Plot No. 104-106 Sector-B Industrial Area, Govindpura, Bhopal - 462 023				
To: <i>Shri Shri Krupa</i>	Bill No: <i>037</i>	Date: <i>29.07.2021</i>		
Plot No. 104-106 Sector-B Industrial Area, Govindpura, Bhopal - 462 023	Bill No: <i>037</i>	Date: <i>29.07.2021</i>		
GSTIN: <i>29AEPK041900001</i>	HSN/SAC: <i>2710</i>	City: <i>INDIA</i>	Rate: <i>110.17</i>	Re Amount: <i>2203.40</i>
PARTICULARS				
CASH				
Total Before Tax: <i>2203.40</i>				
Total After Tax: <i>2203.40</i>				

Handwritten medical report snippet:

Patient Name: *Bhushan M. Deshpande*
 Doctor Round Report
 Reg No: *5421*
 Doctor: *Abhishek Shinde*
 Date: *7/31/2022*
 Time: *7:01 PM*
 Consultant Name: *Abhishek Shinde*
 Advice: *Very critical condition is more to head pain increase day by day. BP increase normal now. V high.*





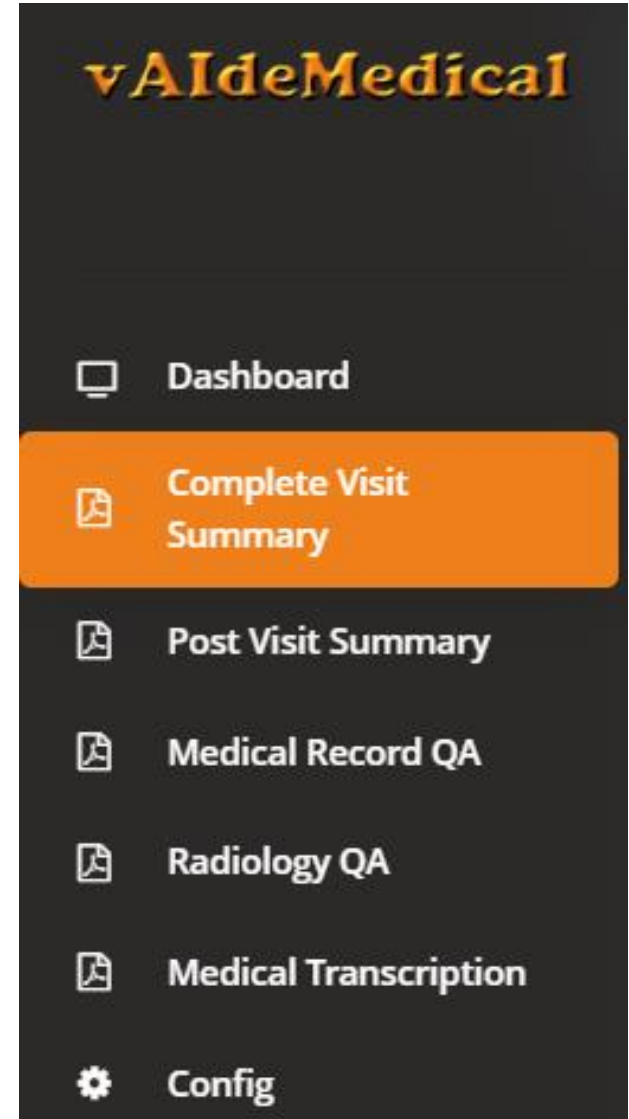
vInnovate Technologies

Healthcare:



vAideMedical Historical Medical Record Analysis and Summary

Taking reports from a patient's long-term medical history, digitizing them, analyzing them, and providing a summary which can be interrogated further using the 'Q&A' option below.





PDF

Download Print More

Patient Name: JOHN A. SMITH MRN: 11111111 MRN: 11111111 MRN: 11111111

Date of Visit: 11 Jun 2015 Doctor: JMM/STC/UCD

Reason Type: CASE

Site Name: View Only MS

Reason For Visit
Abdominal pain (C) in being seen for initial evaluation of group.

History of Present Illness
for unclear reason.

Active Problems
T120 infection (U75.9A) (U01.81)

Surgical History
History of Cholecystectomy
History of Gallbladder Surgery

Family History
No pertinent family history. Mother, Father

Social History
Former smoker (15-20) (20-30) (30-40)
No alcohol use.
No drug use.

Current Medications
No Reported Medications Recorded

Allergies
No known allergies.

History Reviewed
History reviewed. Medications and allergies reviewed.

Review of Systems
Review of Systems: see HPI
Constitutional, Eyes, ENT, Cardiovascular, Respiratory, Gastrointestinal, Genitourinary, Integumentary, Neurological, Psychiatric, Endocrine and Hematology/Immunology are otherwise negative.

Vitals
Vital Signs (Data Includes Current Brunnstrom)
Recorded: 11 Jun 2015

Systolic	112	HR	82
Diastolic	68	RR	16
Temp	37.5	SpO2	98
Weight	75	BP	112/68
Height	5' 10"	HR	82
Temp	37.5	RR	16
Heart Rate	82	SpO2	98
BP	112/68	HR	82

Physical Exam
Constitutional: well developed, normal appearance, well groomed, well nourished, no abnormalities on visual inspection.
Eyes: The conjunctiva exhibited no abnormality and the pupils demonstrated no abnormalities.
ENT: normal oral cavity, no oral pain and no oral lesions.
HEENT: normal pupillary reflexes, 3 nerves present, normal jaw reflexes, 3 nerves present and no upper airway lesions.
Respiratory: no respiratory distress, normal respiratory rhythm and effort, no accessory muscle use and lungs were clear to auscultation bilaterally.
Cardiovascular: heart rate and rhythm were normal, normal S1 and S2 and no murmurs present.

page 7 of 13

Patient Name: JOHN A. SMITH MRN: 11111111 MRN: 11111111 MRN: 11111111

Date of Visit: 11 Jun 2015 Doctor: JMM/STC/UCD

Reason Type: CASE

Site Name: View Only MS

Abdomen well, nondistended, no hepatomegaly and no abdominal masses palpated.
Wound/healed normal post-op site with sufficient for asexual healing.
Extremities: no edema of the extremities, no tenderness, no pathological fractures and no systemic changes.
Pneumatics: normal to normal, clear and clear, but effort was normal. No moist wheezes and no

Upload Reset



PDF

PDF Document Content (Text):

Reason For Visit: [06/13/16] is being seen for an initial evaluation of [shoulder surgery].

History of Present Illness: [shoulder surgery].

Active Problems: [shoulder surgery].

Surgical History: [shoulder surgery].

Family History: [shoulder surgery].

Social History: [shoulder surgery].

Current Medications: [shoulder surgery].

Allergies: [shoulder surgery].

History Reviewed: [shoulder surgery].

Review of Systems: [shoulder surgery].

Vitals: [shoulder surgery].

Physical Exam: [shoulder surgery].

Summary

****[06/13/16]: Pre-operative evaluation****

1. Patient is being seen for pre-operative evaluation prior to shoulder surgery.
2. No pertinent past medical history.
3. No known allergies.
4. Physical exam was unremarkable.
5. Patient is cleared for surgery pending lab results.

****[07/19/16]: Right ankle pain and swelling****

1. 54-year-old female with right ankle pain and swelling following a motor vehicle accident.
2. Has undergone conservative therapy for over a year with minimal to no improvement.
3. MRI of the right ankle showed joint effusion, anterior and posterior talofibular ligament tears, tear of the anteroinferior tibiofibular ligament, longitudinal split tear of the tibialis posterior tendon, retrocalcaneal bursitis and effusion, fluid in the tarsal tunnel.
4. Patient will undergo surgical intervention which includes right ankle arthroscopic debridement, repair of the collateral ankle ligament using Arthrex internal brace system, repair of the syndesmosis using Arthrex TightRope system and application of platelet-rich plasma to the tibialis posterior tendon.

****[08/30/16]: Neck pain with numbness and shooting pain down the arms****

1. 54-year-old female with neck pain and numbness/tingling down her left arm following a bus accident.
2. Has failed conservative care including chiropractic care, physical therapy and cervical injections.
3. MRI of the cervical spine showed evidence of broad-based disc herniation at C5-C6, C6-C7 and C7-T1.
4. Patient will be referred to a spine surgeon for evaluation and possibly candidate for an ACDF.

****[09/09/16]: Right hand pain****

1. 54-year-old female with right hand pain following a motor vehicle accident.
2. Has significant pain in the hand with grasping activities, lifting, twisting, turning doorknobs, and pinching.
3. MRI of the right hand showed tear of the ulnar collateral ligament of the MCP joint of the thumb. There is also question of a partial tear of the flexor tendon of the thumb as well as flexor tendon injury to the index finger.
4. Patient will undergo surgical repair of the UCL ligament.

Upload

Reset

Export as pdf

Summarize



vInnovate Technologies

Healthcare:



vAideMedical


Post Visit Report Analysis & Summary

Taking information from a single patient's medical visit, digitizing it, analyzing it, and providing a summary.

The process looks very similar to the previous Use Case, with the same outcome, but applied to a single appointment report.

vAideMedical

 Dashboard


 Complete Visit
Summary

 **Post Visit Summary**

 Medical Record QA

 Radiology QA

 Medical Transcription

 Config



vInnovate Technologies

Healthcare:



vAideMedical Medical Record Question & Answer

Allowing free-form text enquiries of a record, however long and complex, to obtain clarity and receive professional analyses.

vAideMedical

- Dashboard
- Complete Visit Summary
- Post Visit Summary
- Medical Record QA**
- Radiology QA
- Medical Transcription
- Config



PDF

1 / 6 | - + | ↺

↓ Print ⋮

SYNERGY CHIROPRACTIC CLINICS
1250 S. Sheridan Blvd.
Denver, CO, 80232
Ph: 303-937-7119
Fax: 303-568-9331

INITIAL EVALUATION

PATIENT: Lujan, Gloria **DOB:** 1949-01-07
EXAMINATION DATE: 2020-03-02
DATE OF INJURY: 2019-11-28
Examining Doctor: Gregory Karraker, DC

HISTORY OF ACCIDENT:
The patient was a restrained driver of her moving automobile. She stated, "I was heading SB on Pardee St, going through an intersection. The GMC truck was EB on W. Florida Ave. The vehicle slid through the red light and T-boned the passenger side of my vehicle pushing me close to a pole." There were no secondary collisions. There was no airbag deployment. The patient stated that they did brace for impact as she saw the collision about to happen. There was no loss of consciousness. She stated that she was thrown from side to side and hit her head on the window and door. The patient reported being physically shaken for about a week after the collision.

TESTING/TREATMENT TO DATE:
She stated that she was treated by the paramedics on the scene but declined an ambulance ride to the hospital. The symptoms continued to worsen and she drove herself to Swedish Medical Center for treatment. The patient reports having x-rays/CT scans taken of her neck, back and left shoulder and states that she was told they were negative for fractures. Reports will be requested for review. She has treated with her PCP around three times and has been to Select Physical therapy around five times. She has also been to Kaiser around four times since the collision. She has not been feeling any better and decided to call to schedule an appointment for an evaluation with Synergy.

CHIEF COMPLAINT(s):

1. Headaches
2. Neck pain
3. Upper back pain
4. Mid back pain
5. Lower back pain
6. Left shoulder pain
7. Rib pain
8. Left wrist pain

Sleep - The patient is having trouble sleeping due to the pain from the injuries she

Upload Reset

What are the patient's and her family's medical histories?

PDF

1 / 6 | - + ↺

SYNERGY CHIROPRACTIC CLINICS
 1250 S. Sheridan Blvd.
 Denver, CO, 80232
 Ph: 303-927-7119
 Fax: 303-568-9331

INITIAL EVALUATION

PATIENT: Lujan, Gloria **DOB:** 1949-01-07
EXAMINATION DATE: 2020-03-02
DATE OF INJURY: 2019-11-28
Examining Doctor: Gregory Karraker, DC

HISTORY OF ACCIDENT:
 The patient was a restrained driver of her moving automobile. She stated, "I was heading SB on Parcer St, going through an intersection. The GMC truck was EB on W. Florida Ave. The vehicle slid through the red light and T-boned the passenger side of my vehicle pushing me close to a pole." There were no secondary collisions. There was no airbag deployment. The patient stated that they did brace for impact as she saw the collision about to happen. There was no loss of consciousness. She stated that she was thrown from side to side and hit her head on the window and door. The patient reported being physically shaken for about a week after the collision.

TESTING/TREATMENT TO DATE:
 She stated that she was treated by the paramedics on the scene but declined an ambulance ride to the hospital. The symptoms continued to worsen and she drove herself to Swedish Medical Center for treatment. The patient reports having 6-rays/ CT scans taken of her neck, back and left shoulder and states that she was told they were negative for fractures. Reports will be requested for review. She has treated with her PCP around three times and has been to Select Physical therapy around five times. She has also been to Kaiser around four times since the collision. She has not been feeling any better and decided to call to schedule an appointment for an evaluation with Synergy.

CHIEF COMPLAINT(s):

1. Headaches
2. Neck pain
3. Upper back pain
4. Mid back pain
5. Lower back pain
6. Left shoulder pain
7. Rib pain
8. Left wrist pain

Sleep - The patient is having trouble sleeping due to the pain from the injuries she

Export as pdf

Upload Reset

Chat

You
What are the patient's and her family's medical histories?

You
 Patient's Medical History: - Left knee replacement in 2016 - Right knee replacement in 2012 - Two prior automobile collisions around 15 years ago, no bodily injuries - One prior work related injury in 1982 - Cervical fusion levels C3-C5 - Pain in the left shoulder, upper arm, wrist, and hand - Cervical radiculopathy (pain, numbness, or tingling in the neck and shoulders) - Lumbar radiculopathy (pain, numbness, or tingling in the lower back and legs) - Sprain of the ribs - Strain of the chest musculature - General anxiety reaction - Sleep disorder - High blood pressure **Patient's Family Medical History:** - Mother: Pancreatic cancer, Diabetes - Father: Heart condition

Submit

What are the patient's and her family's medical histories?

Submit



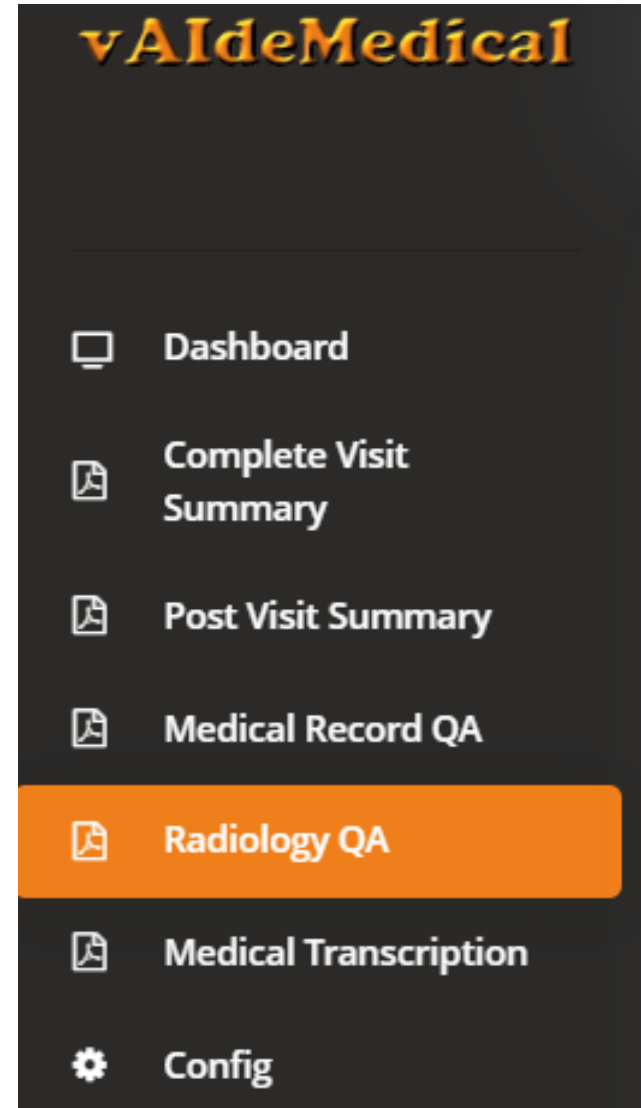
vInnovate Technologies

Healthcare:



vAldeMedical Radiology Analysis

Taking information from X-Rays, CT or MRI Scans and asking for medical analyses, interpretations and recommendations.





image

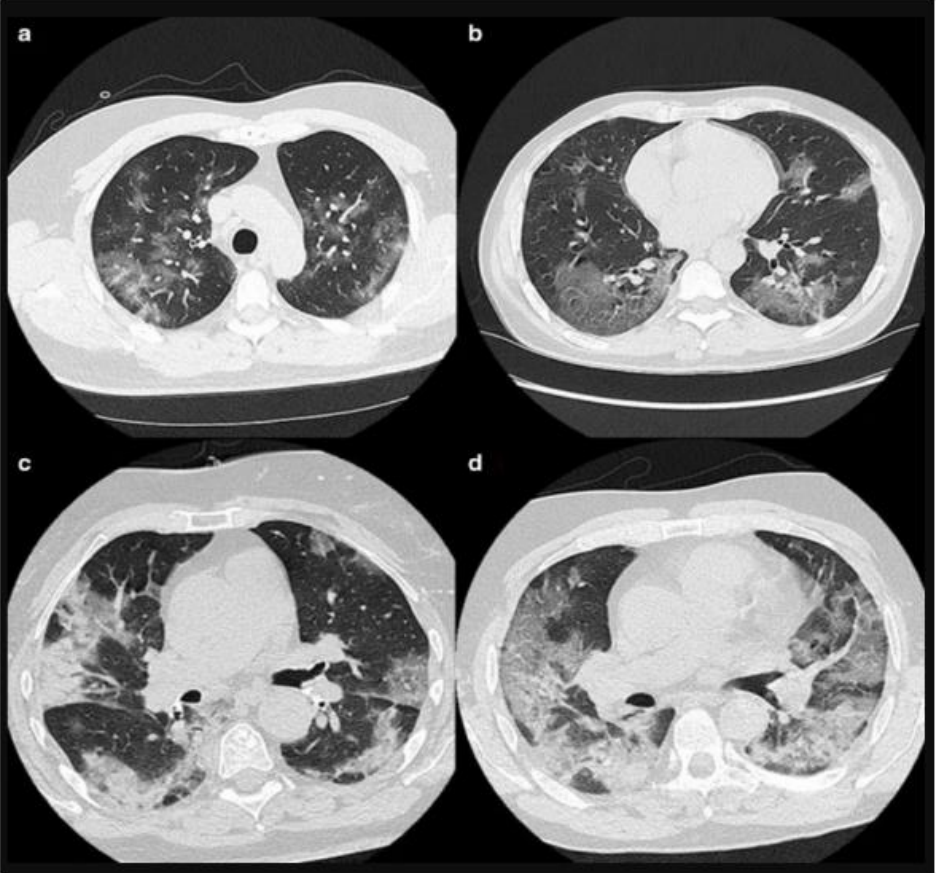
Chat

What do these scans show, and is there any evidence of medical trauma?

Submit



Image



Chat

You: What do these scans show, and is there any evidence of medical trauma?

You: These scans show bilateral ground-glass opacities in the lungs, which is a common finding in patients with COVID-19. There is no evidence of medical trauma.

Export as pdf

Upload Reset

What do these scans show, and is there any evidence of medical trauma?

Submit



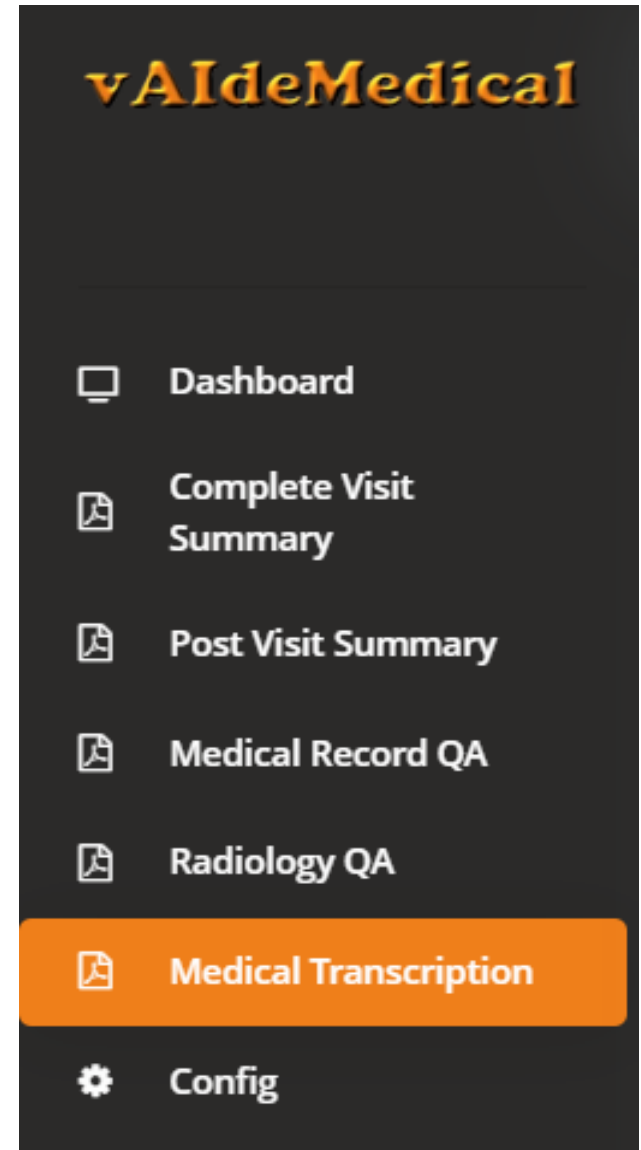
vInnovate Technologies

Healthcare:



vAldeMedical Medical Transcription

Transcribing voice recordings of patient reports, interviews, etc. and converting them to digital text for analysis, summarization and incorporation into composite reports and summaries.





vInnovate Technologies

Medical Transcription

🔊 Audio



0:00

1:01



1x



Status

Audio Processed

Transcribe

Summarize



Vinnovate Technologies

Medical Transcription

Audio ⌵ ✕

0:00 1:01

1x

⏮ ⏪ ⏩ ⏭

🔄 ✂

📶 🎤

The audio player interface includes a waveform at the top, a progress bar below it, and a volume control icon with a '1x' multiplier. Playback controls include a play button, a previous button, a next button, a refresh button, and a split button. At the bottom, there are icons for upload and microphone input.

Status

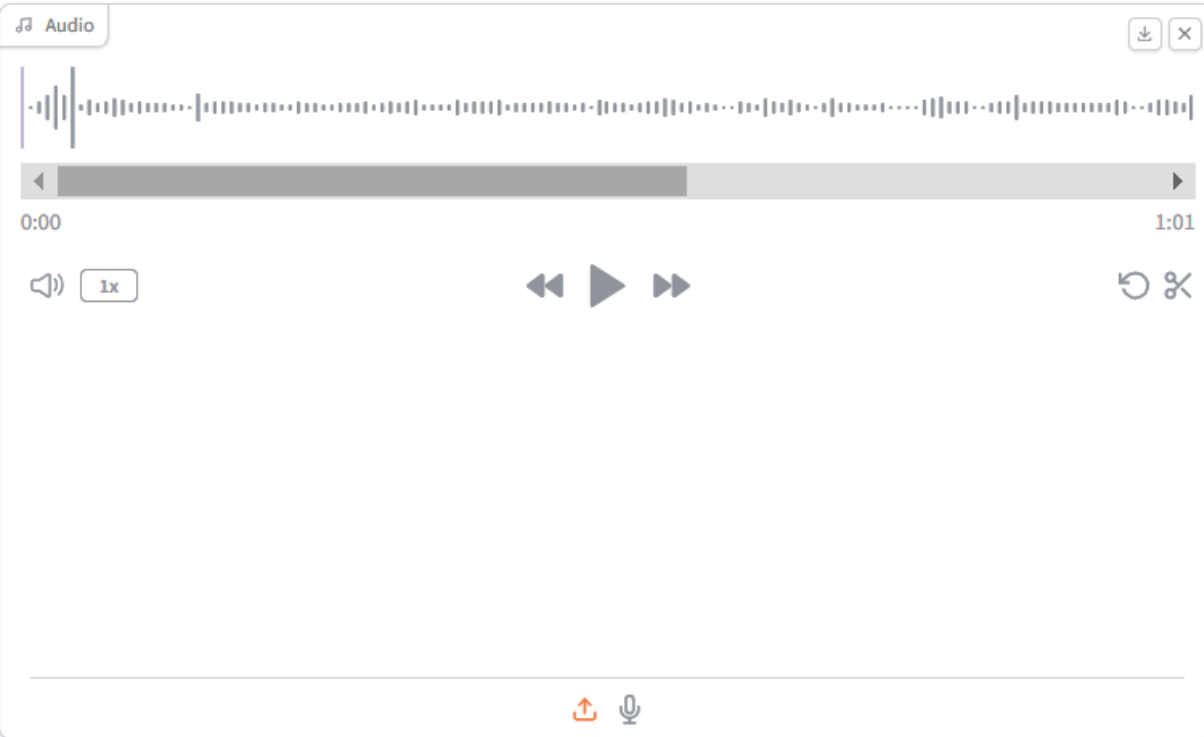
Audio Processed

Transcribe

Summarize

Medical Transcription

Audio Download Close



0:00 1:01

1x

Upload

Status

Audio Processed

Transcribe


Summarize

Transcription

This is a follow-up note. Subjective. The patient is back today reporting about 50% improvement. Basically, he went from almost completely disabled with this issue to now being very functional. He can still push at i.e. he was at the garden of the gods this weekend. And anytime the giant hybrid extends, he will get some pain on more of the dorthal side. He did have some pain in that situation on the planter side, but that went away over the last week. Physical exam. On exam, ultrasound is used, which show was no effusion noted. There was still some insi longer needed to use the toe straightener and s Assessment marked improvement in planter pl juncture, we are going to give this another two whether or not we need any further treatment.

Medical Transcription

Audio Download Close



0:00 1:01

Volume: 1x Previous Play Next Refresh Scissors

Upload Microphone

Status

Audio Processed

Transcribe


Summarize

Transcription

This is a follow-up note. Subjective. The patient is back today reporting about 50% improvement. Basically, he went from almost completely disabled with this issue to now being very functional. He can still push at i.e. he was at the garden of the gods this weekend. And anytime the giant hybrid extends, he will get some pain on more of the dorthal side. He did have some pain in that situation on the planter side, but that went away over the last week. Physical exam. On exam, ultrasound is used, which show was no effusion noted. There was still some insi longer needed to use the toe straightener and s Assessment marked improvement in planter pl juncture, we are going to give this another two whether or not we need any further treatment.

Medical Transcription

Audio Download Close



0:00 1:01

Speaker 1x Previous Play Next Refresh Scissors

Upload Microphone

Status

Audio Processed

Transcribe

Summarize

Transcription

This is a follow-up note. Subjective. The patient is back today reporting about 50% improvement. Basically, he went from almost completely disabled with this issue to now being very functional. He can still push at i.e. he was at the garden of the gods this weekend. And anytime the giant hybrid extends, he will get some pain on more of the dorthal side. He did have some pain in that situation on the planter side, but that went away over the last week. Physical exam. On exam, ultrasound is used, which shows better organization of the planter side. Sorry, planter plate. There was no effusion noted. There was still some instability, medial collateral. He was no longer needed to, he has no longer needed to use the toe straightener and still has some mild vougas. The joint is completely non-tender today. Assessment marked improvement in planter plate injury and first metatarsal phallangelo osteoarthritis. At this juncture, we are going to give this another two months to see how it fully heals. At that juncture, we will decide whether or not we need any further treatment.

Summary

The patient presented with a planter plate injury and first metatarsal phalangeal osteoarthritis, experiencing significant improvement with about 50% reduction in symptoms. The patient went from being almost completely disabled to now being very functional, able to engage in activities such as hiking. Ultrasound examination showed better organization of the planter plate with no effusion noted. There is still some instability in the medial collateral, but the patient no longer needs to use a toe straightener and only experiences mild pain. The joint is non-tender. The plan is to monitor the patient for another two months to assess full healing before deciding on further treatment.



vInnovate Technologies



Healthcare:

vAldeMedical Benefits



Patient Benefits:

- **Improved care and faster diagnosis:** Generative AI can analyze vast amounts of historical data to identify patterns and trends that might be missed by humans. This can lead to more accurate preventive and predictive diagnoses and personalized treatment plans.
- **Enhanced communication and information access:** Generative AI can be used to create easy-to-understand reports and summaries of a patient's medical history, allowing for better communication between patients and clinicians.
- **Streamlined data collection:** AI can automate tasks such as data entry from medical devices or wearables, reducing the burden on patients and ensuring more complete data capture.



vInnovate Technologies



Healthcare:

vAldeMedical Benefits



Clinical and Hospital Benefits:

- **Increased efficiency and productivity:** Generative AI can automate repetitive tasks such as data collection, cleaning, validation and analysis, freeing up staff time to focus on more critical activities like patient care and better clinical outcomes.
- **Better decision-making:** Generative AI can quickly analyze data to identify potential risks and complications, allowing healthcare professionals to make more informed decisions about patient care.
- **Scalable, to cope with increasing workloads:** Whilst still offering your patients better care and better services due to its advanced technologies.



vInnovate Technologies



Healthcare:

vAldeMedical Benefits



Overall System Benefits:

- **SaaS (Cloud-hosted) as well as on-Premise offerings:** Ensures data confidentiality and security.
- **Customizable & easy to integrate with existing client platforms:** Offering overall efficiency in the management of patient data.
- **Integrated with the latest advanced generative AI technologies:** Including Google MedLM, Open AI, Google Gemini, Google Cloud, and Microsoft Azure AI platform.
- **Cost Effective & Ready for Market:** We are an established technology company providing cutting edge products & solutions in healthcare around the world, under guidance of experts in the field.



vInnovate Technologies



Would you like to find out more



+91-8982474162 | +91-9823475566



contact@vinnovatetechnologies.com



www.vinnovatetechnologies.com